



# Avascular necrosis of the shoulder

Michail Klontzas, MD, PhD

Radiology Resident, University Hospital of Heraklion

SSMR 2022 - Heraklion

DECOMPRESSION SYNDROME IN PLESIOSAURS (SAUROPTERYGIA: REPTILIA)

BRUCE M. ROTHSCHILD<sup>1</sup> and GLENN W. STORRS<sup>2</sup>


<sup>1</sup>Arthritis Center of Northeast Ohio, Youngstown, Ohio 44512; Northeastern Ohio Universities College of Medicine, Youngstown, Ohio 44272, bmr@neoucom.edu; The Carnegie Museum, Pittsburgh, Pennsylvania 15213;

University of Kansas Museum of Natural History, Lawrence, Kansas 66045;

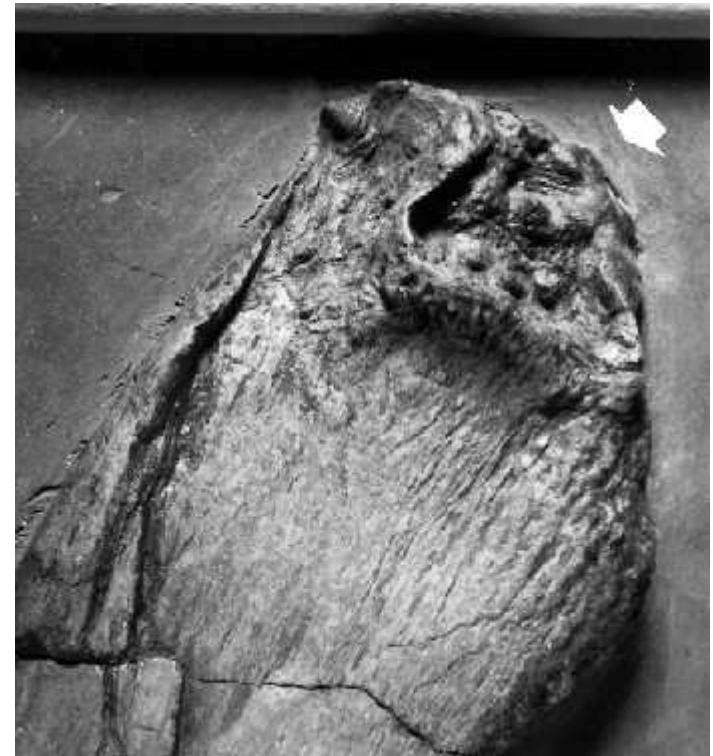<sup>2</sup>Cincinnati Museum Center, Geier Collections and Research Center, 1301 Western Ave., Cincinnati, Ohio 45203-1127

# Epidemiology

2<sup>nd</sup> most common (hip 1<sup>st</sup>)

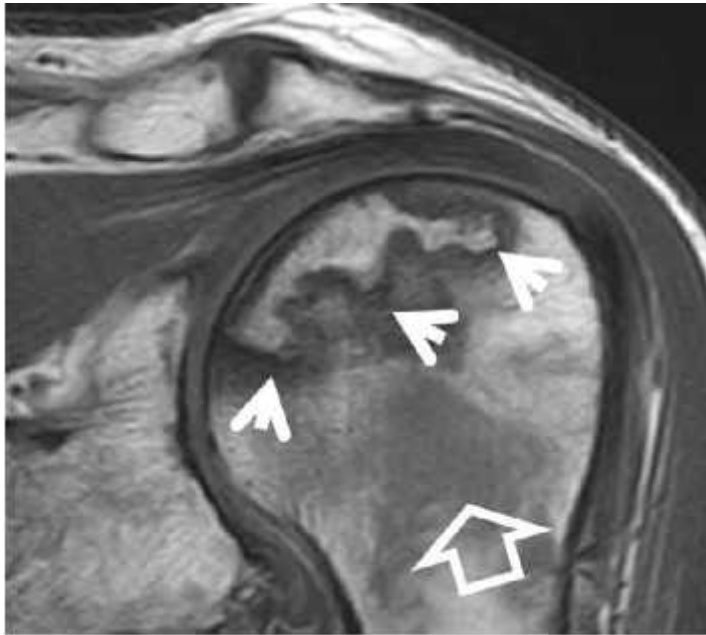


Plesiosaurus - a keen diver living 199 mil years ago

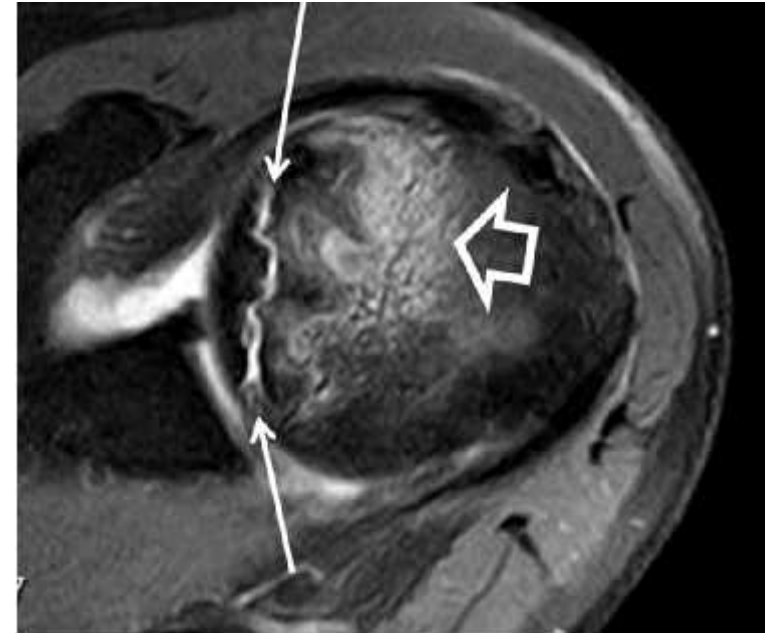


# Imaging findings

Band-like sign

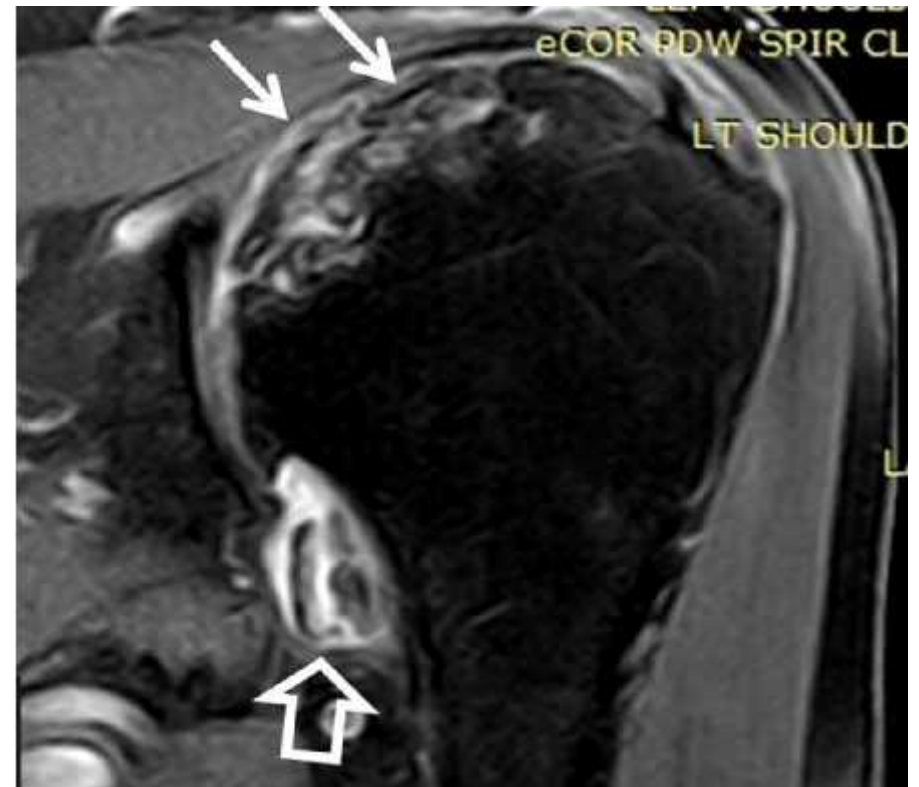
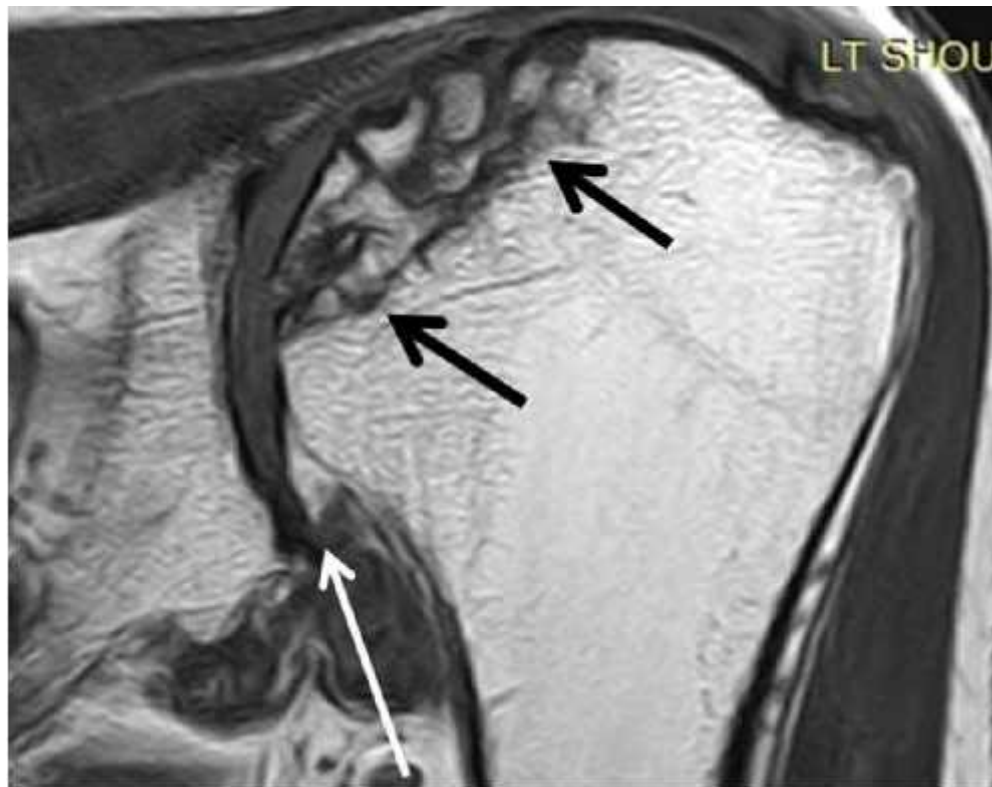
Crescent sign

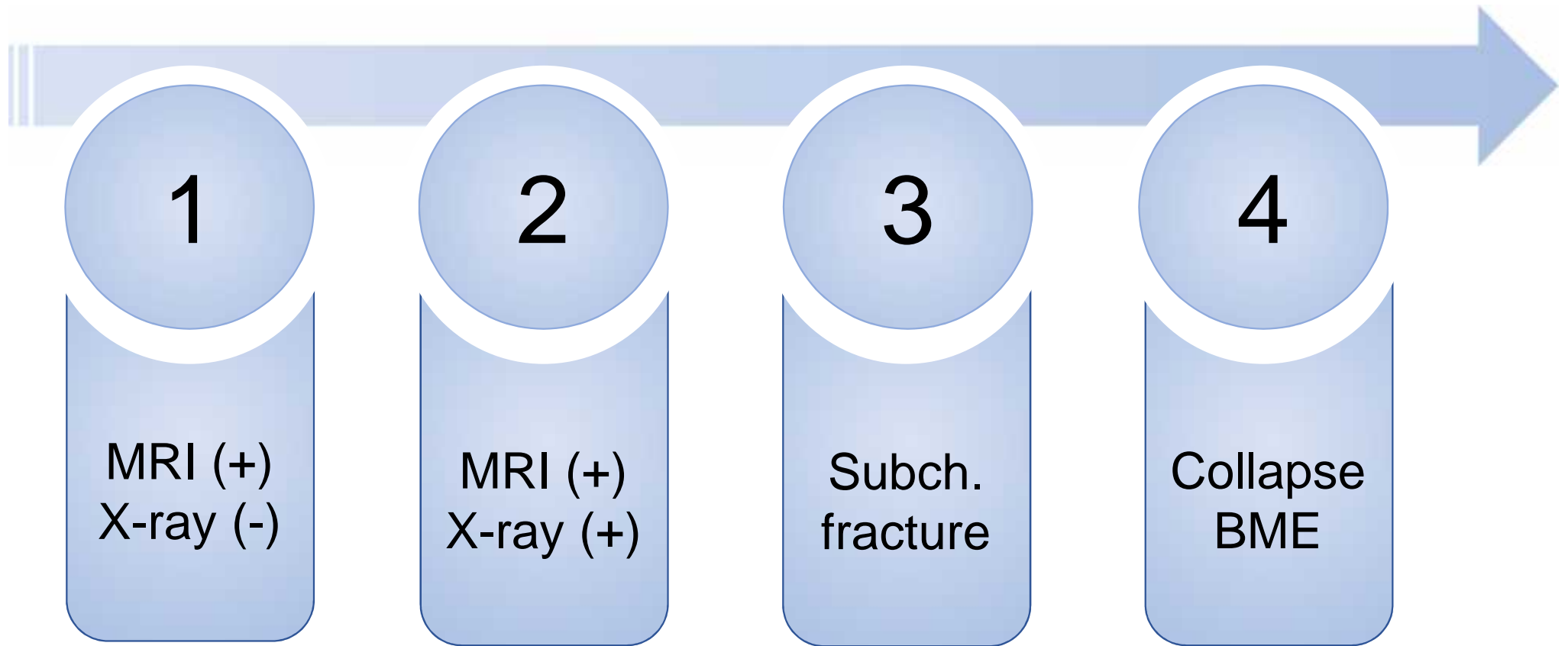


- SOS – double line sign = DO NOT USE (chemical shift artefact)

# Imaging findings

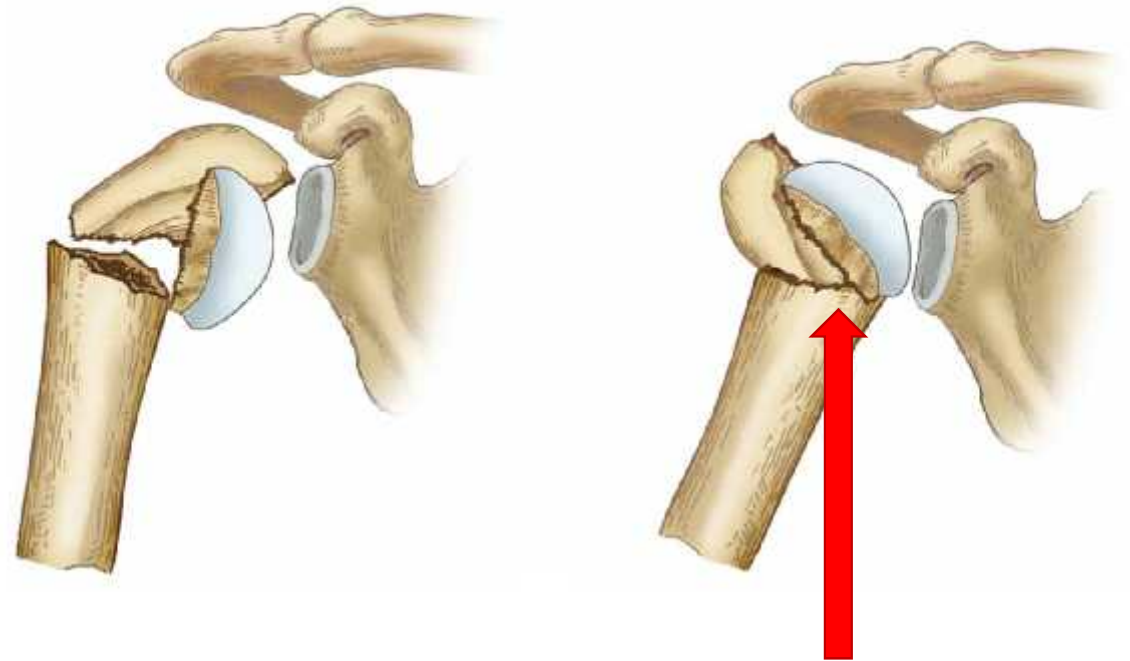
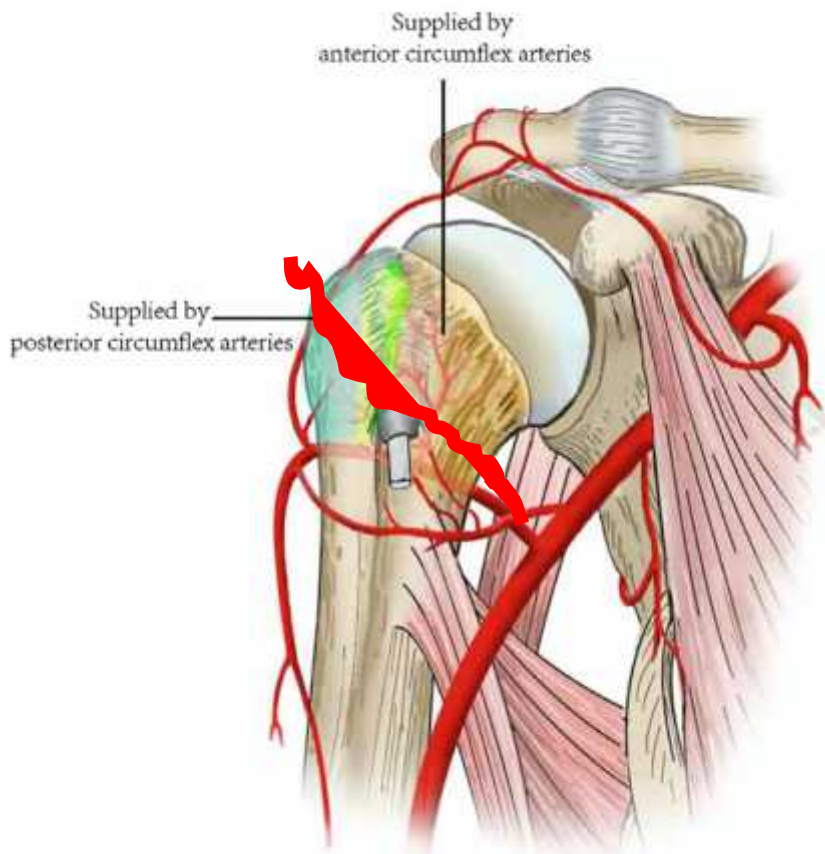


# Grading





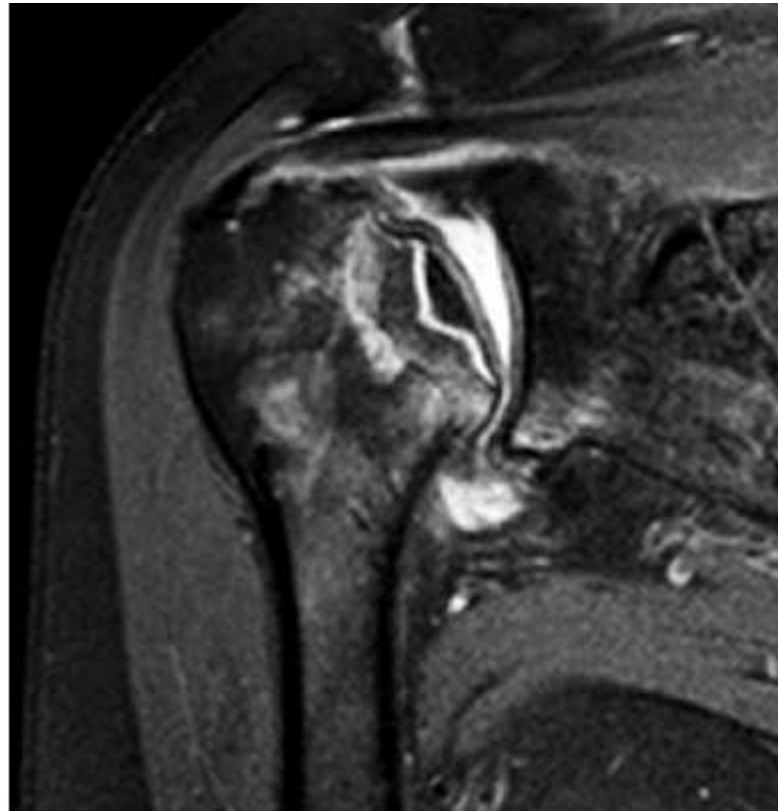
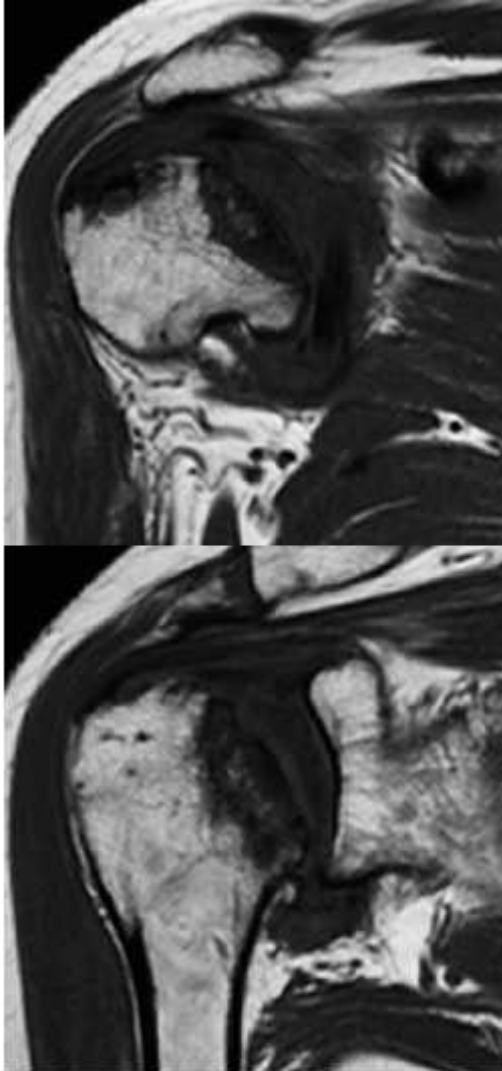# Anatomy first...



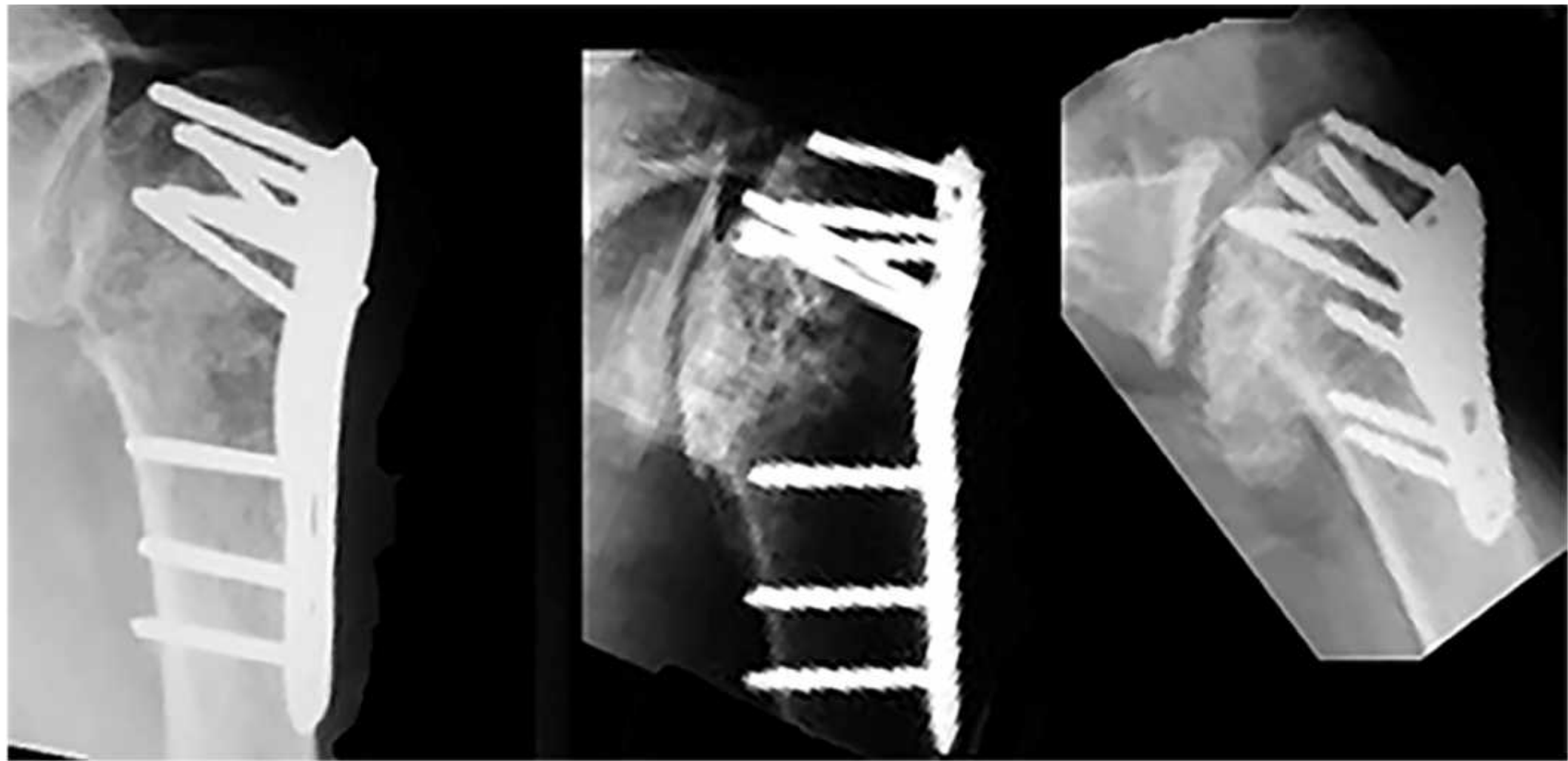
Incidence:  
3-part: 0-25%  
4-part: 0-77%

Esser RD, J Orthop Trauma, 1994  
Greiner S et al., Injury 2009  
Hernigou P et al. Orthop Surg 2020

# Fall from height - fracture

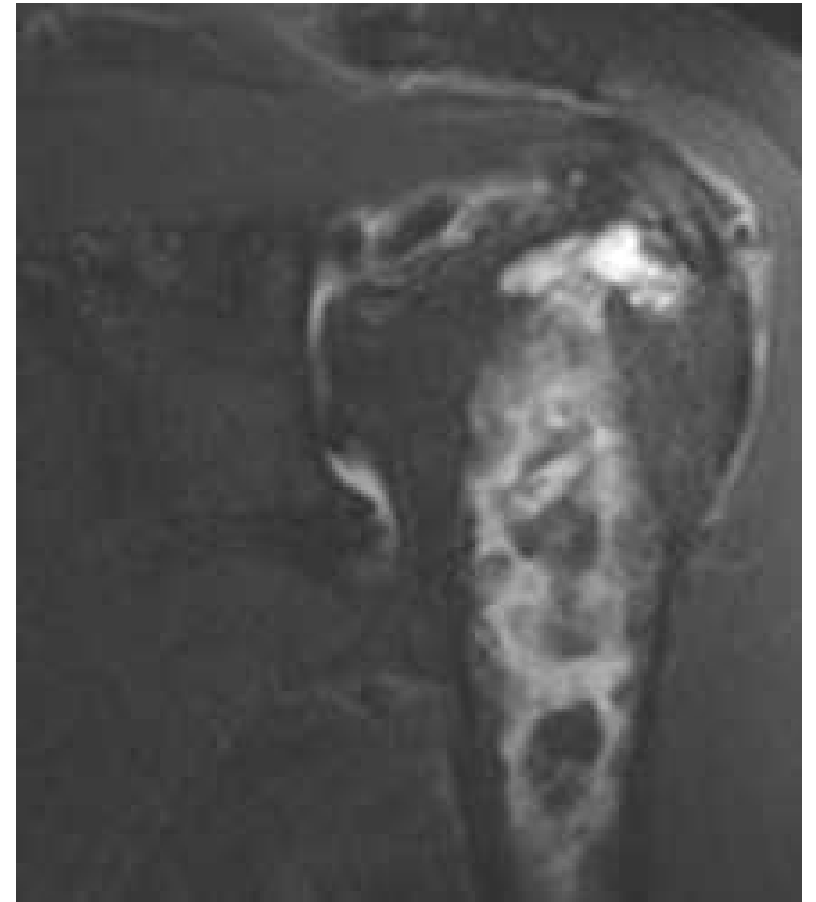
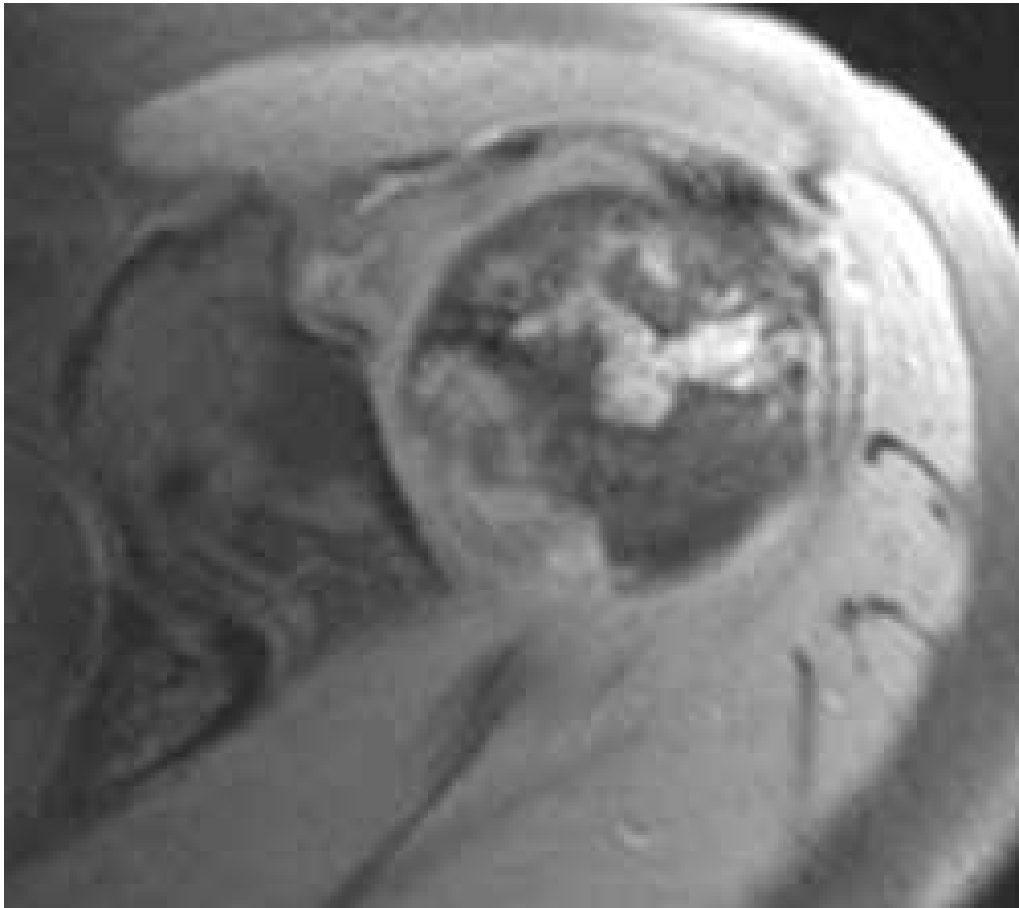


- 64F
- Conservative treatment
- 2y post-trauma
- 4 months - pain





61 y/o female under steroids





# Pathophysiology please...??!!

- BM fat accumulation – increased pressure – low blood flow

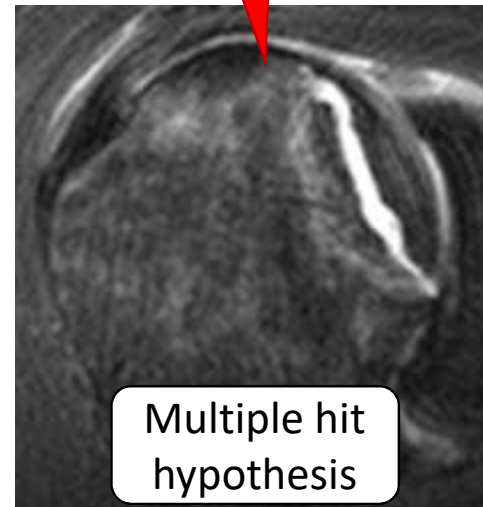Dose response?  
Threshold?  
Peak-dose?

High doses in the beginning seem more correlated

Bone cell toxicity

Suppression of precursor differentiation

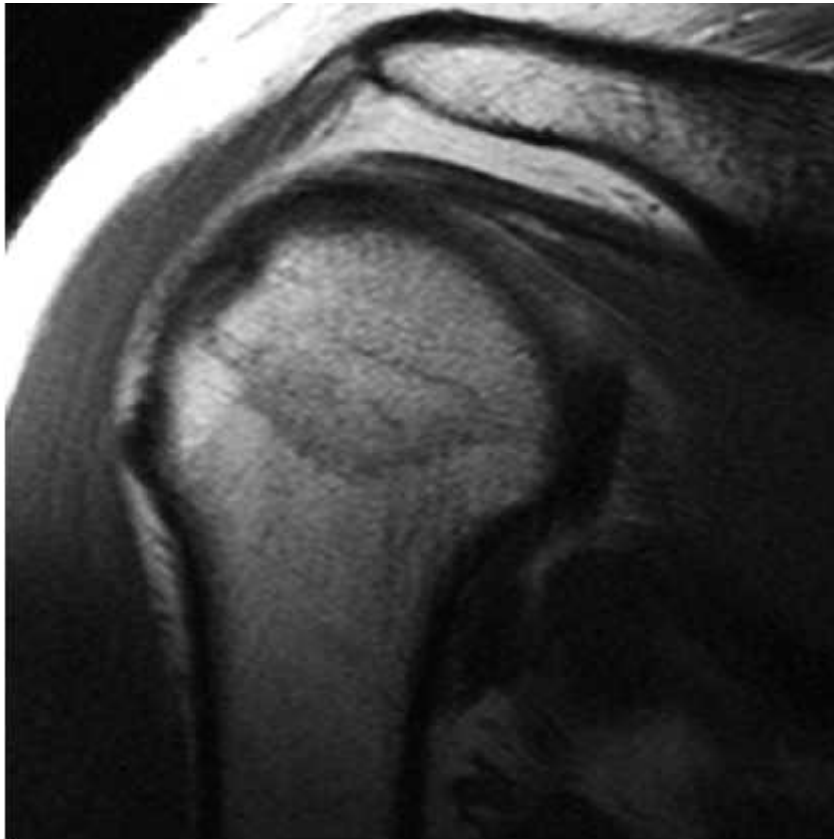
Blood flow impairment



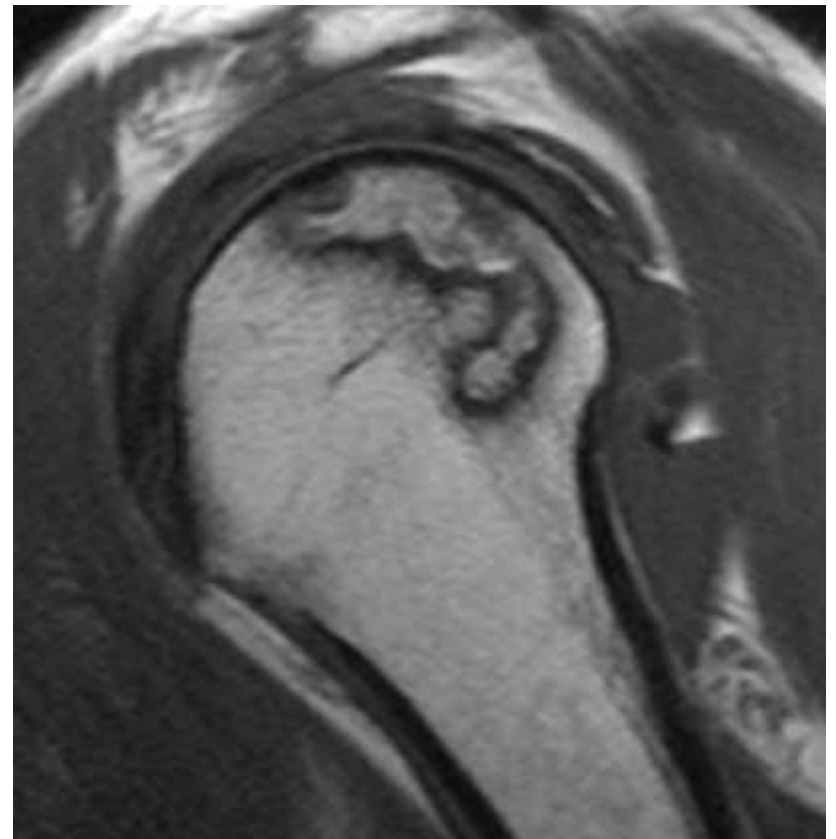
Multiple hit hypothesis

46m histiocytosis

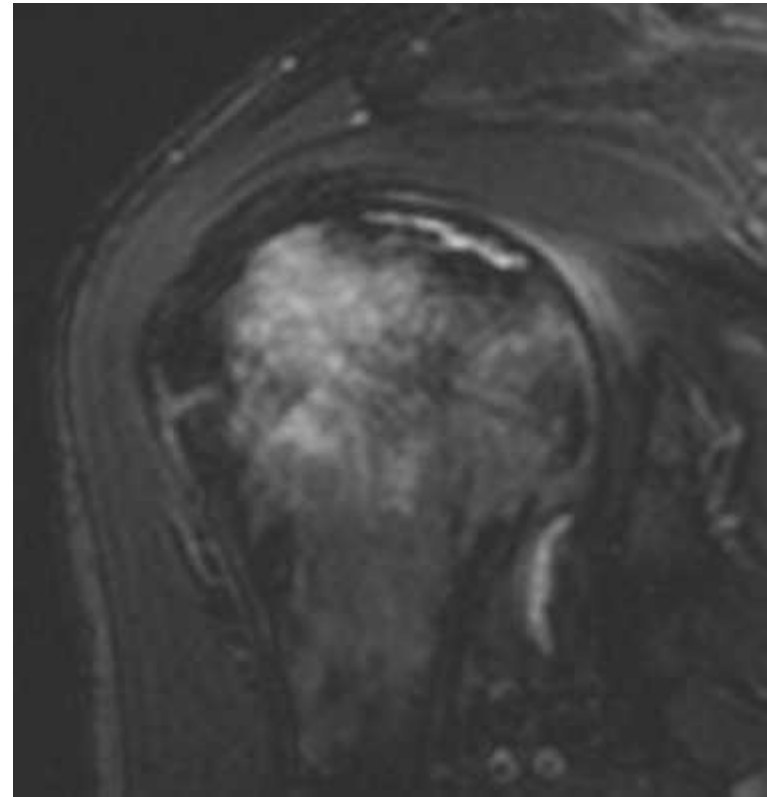
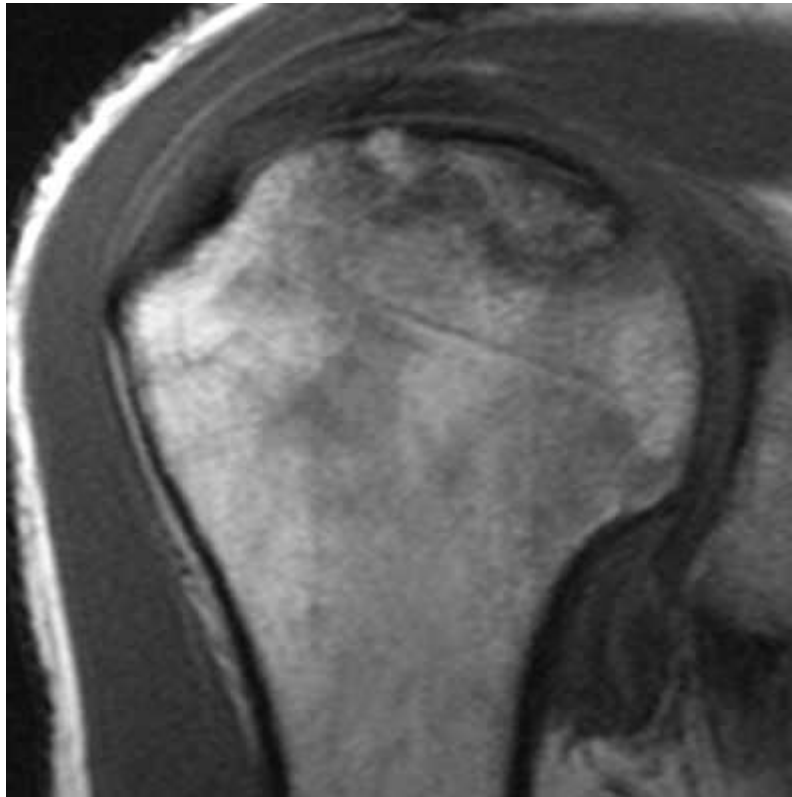
Immediate post-radiotherapy

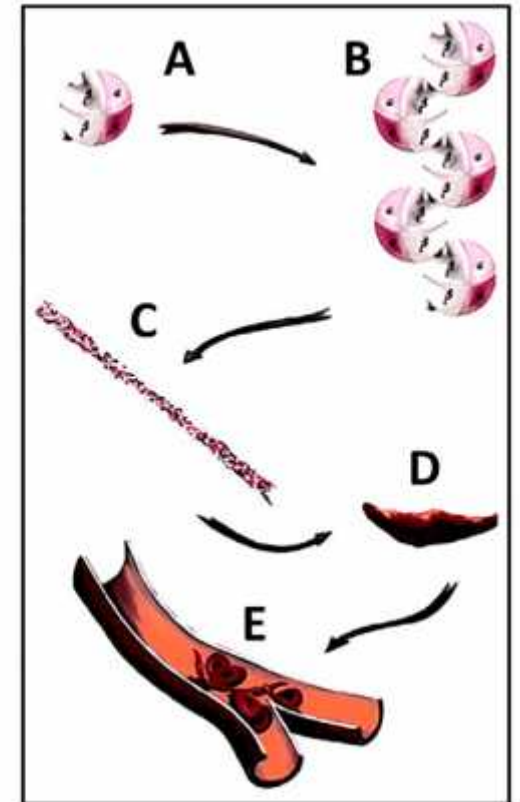
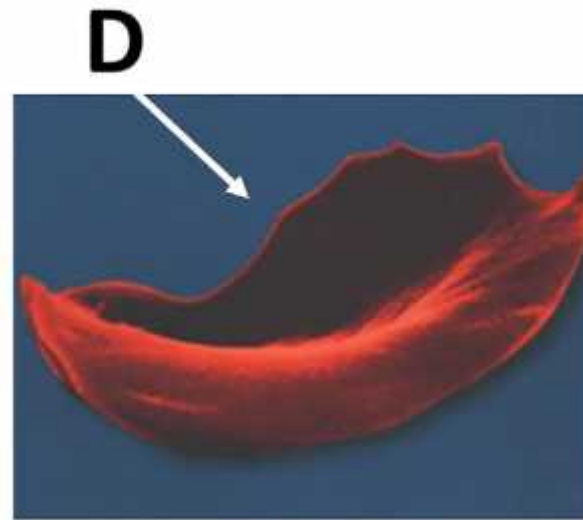


1.5y  
→



Hematological disease – 36y/o thrombophilia

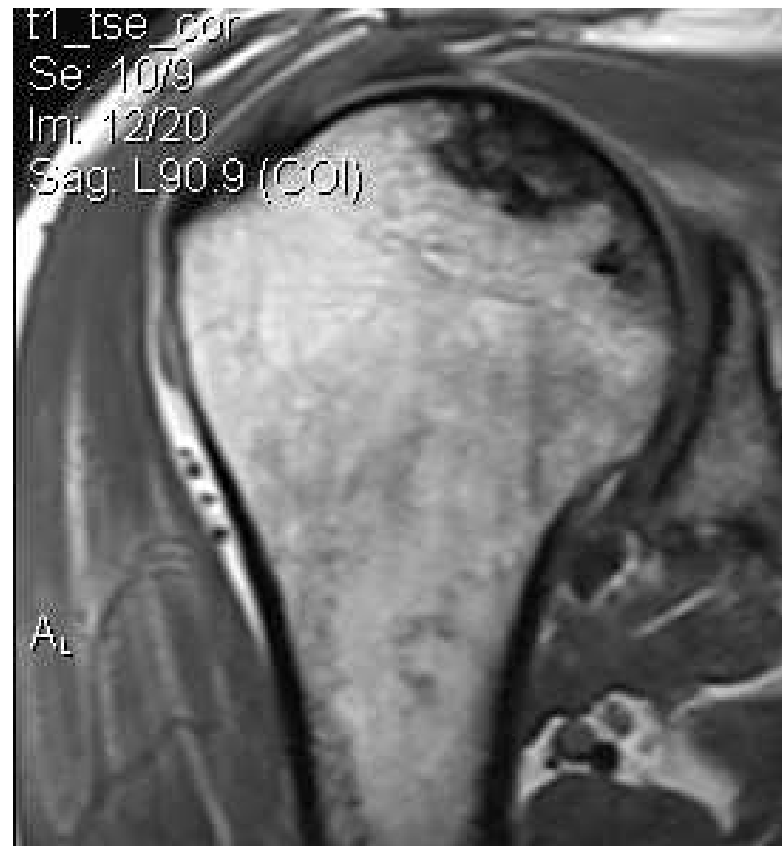
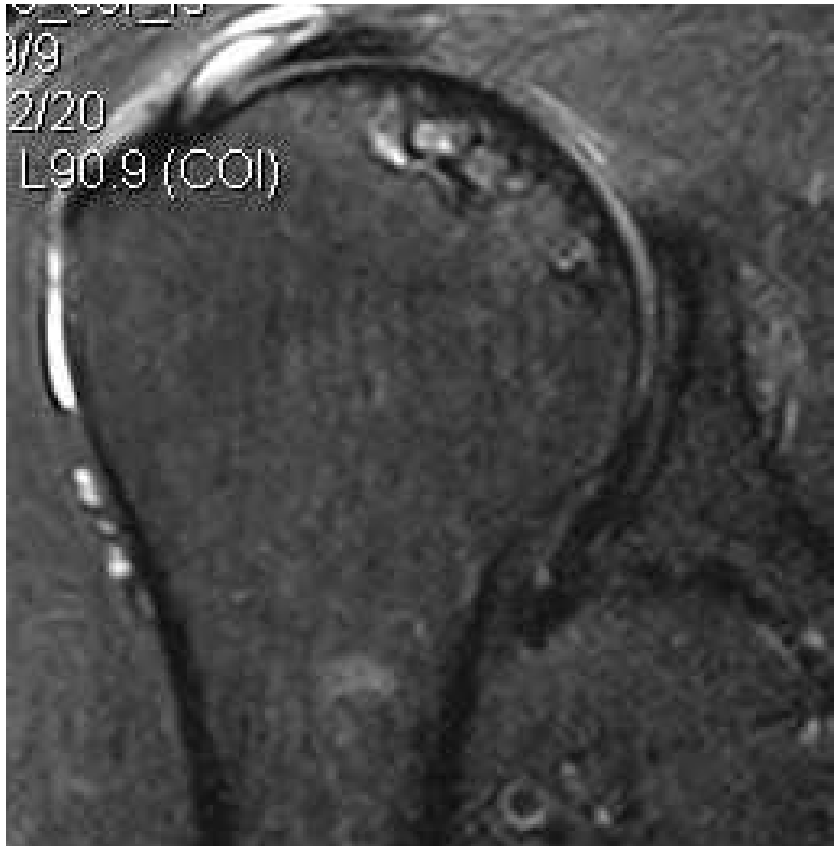


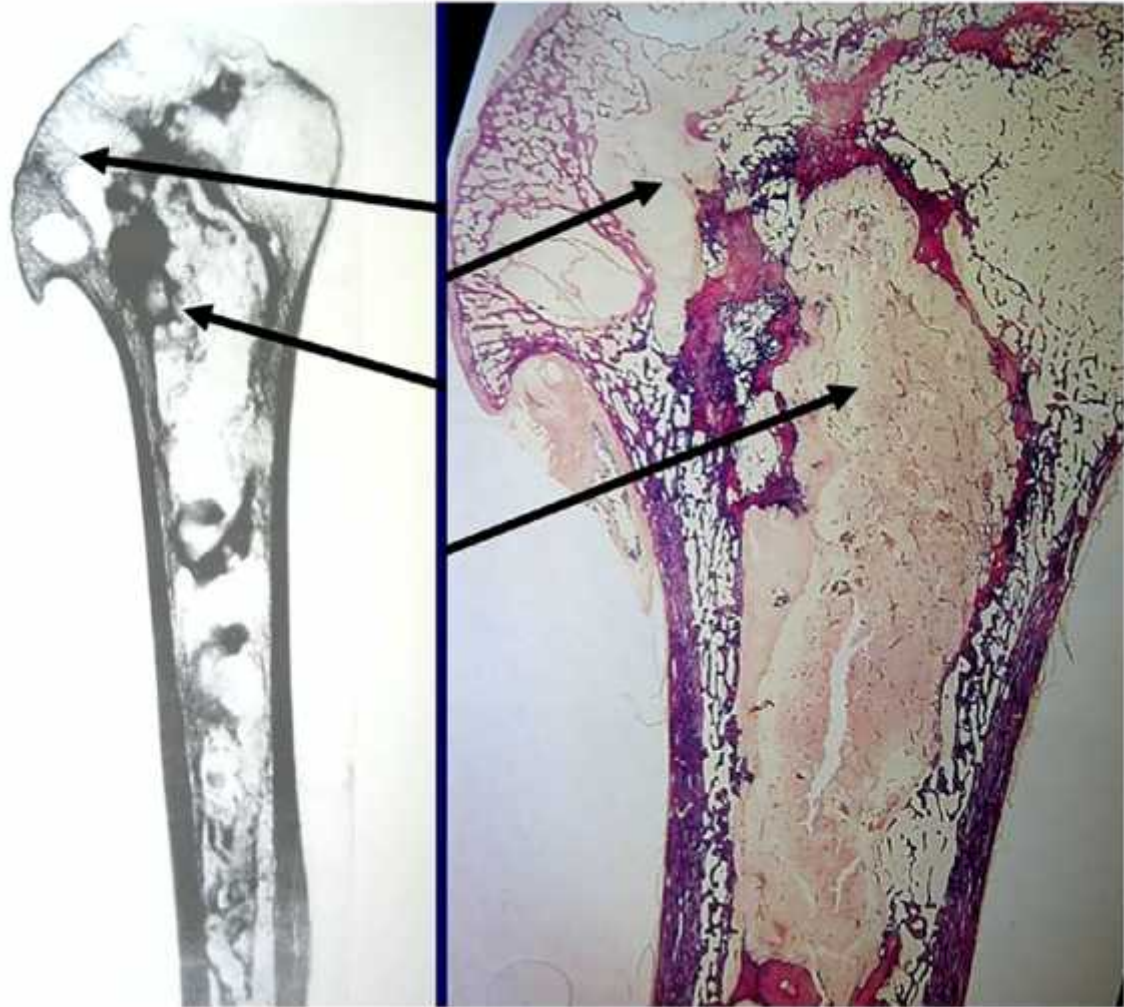
- Collapse in 86% of shoulders
- 6 years from onset of pain to collapse

20 years of follow-up – Poignard A et al. JBJS 2012

# Decompression accidents - divers

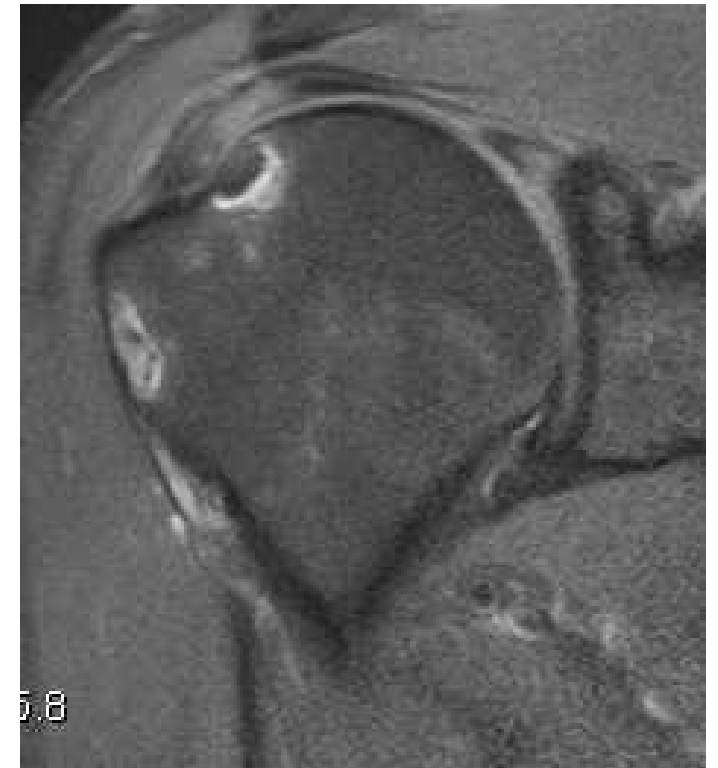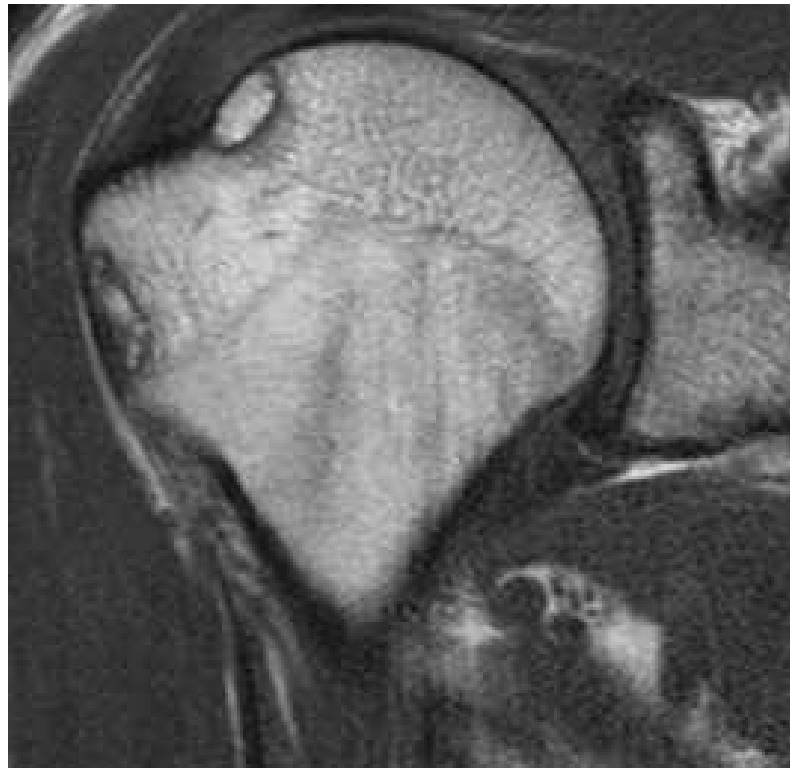






# Cannot find a cause?

- Idiopathic



Take home....

**MRI method of choice –  
diagnosis and grading**

Thank you!

